

Dismembering Bodies for Display: A Bioarchaeological Study of Trophy Heads from the Wari Site of Conchopata, Peru

Tiffany A. Tung

Department of Anthropology, Vanderbilt University, Nashville, TN 37235

KEY WORDS Ritual; Andes; Huari; Body Mutilation; Violence

ABSTRACT Human trophy heads from the Wari site of Conchopata (AD 600–1000) are examined to evaluate if recently deceased persons or old corpses were used to make trophy heads and determine if the modifications are standardized. Similarly styled trophy heads may suggest state oversight that ensured uniform modifications, while different styles may suggest that various factions or kin groups prepared them to their own specifications. Other studies often interpret trophy heads as either enemies or ancestors; so, this study addresses that debate by documenting aspects of their identity as revealed through demographic, paleopathological, and trauma data. Results show that “fresh” bodies, not old corpses, were used to make trophies, as evidenced by cutmarks indicating intentional removal of soft tissues. Trophy heads are remarkably

standardized; 89% display a hole on the superior of the cranium, apparently a design feature that displays the trophy head upright and facing forward when suspended by a cord. Of the 31 trophy heads, 24 are adolescents/adults and 7 are children, and of the 17 sexed adults, 15 are male and 2 are female. This suggests that adult men and children were favored as trophies. Among 19 observable adult trophy heads, 42% exhibit cranial trauma, suggesting that violence was common among this group. Complementary data on Wari iconography shows warriors wearing trophy heads and Wari deities holding captives and trophy heads. Thus, it is likely that captives (or just their heads) were taken in battles and raids—either secular or ritual—and eventually transformed into trophy heads. *Am J Phys Anthropol* 136:294–308, 2008. © 2008 Wiley-Liss, Inc.

Isolated human heads and trophy heads have been recovered from various prehispanic sites in the Andes, affiliated with cultural groups such as Chavin, Moche, Nasca, Tiwanaku, and Inka. Among the Wari (AD 600–1000), however, only iconography hinted at the possibility of head taking and trophy head display (Cook, 2001), but with recent analysis of isolated human skulls from the Wari site of Conchopata in Ayacucho, Peru, it is now clear that this prehispanic empire also engaged in these practices. These 31 trophy heads are the first and, to date, only to be directly associated with the Wari empire.¹

To gain insights into what these human trophy heads may have represented in Wari society, this article describes anthropogenic alterations to the skulls, documenting modifications such as drilled holes, cutmarks, and chopmarks. The osteological modifications are also examined to evaluate the level of standardization in terms of how the trophy heads were prepared and displayed. Were they created by various factions or kin groups, each with their own ideas and methods regarding how trophy heads should be processed and displayed? Or was there a special class of individuals tasked with processing the bodies in a uniform manner, resulting in similarly styled trophy heads for use in specific rituals?

Detailed osteological analysis of the trophy heads can aid in addressing these questions, particularly if those

data are evaluated in tandem with iconographic and archaeological evidence. If the trophy heads are modified in different ways and appear in different contexts, then it may be suggested that separate factions or kin groups were authoring the various styles and uses of the trophy heads. If, in contrast, the trophy heads are similarly modified and appear in similar contexts, particularly in comparison to Nasca trophy heads from south-central Peru, then it may be suggested that their preparation and ritual use were monitored to ensure particular standards and perhaps control the message that the heads were meant to convey.

Commonly, debates about trophy heads focus on their identity as either venerated ancestors or vanquished enemies, though other identities, such as executed criminals, social outcasts, or venerated sacrificial victims, should be considered as well. In an attempt to recon-

Grant sponsor: National Science Foundation; Grant number: BCS-0118751; Grant sponsor: Wenner-Gren Foundation for Anthropological Research; Grant number: 6680; Grant sponsors: Fulbright IIE Fellowship, Sigma Xi Grants in Aid of Research, University of North Carolina-Latané Summer Research Grant.

*Correspondence to: Tiffany A. Tung, Department of Anthropology, Vanderbilt University, VU Station B #356050, Nashville, TN 37235, USA. E-mail: t.tung@vanderbilt.edu

Received 5 September 2007; accepted 28 December 2007

DOI 10.1002/ajpa.20812

Published online 6 March 2008 in Wiley InterScience (www.interscience.wiley.com).

¹There are two other known trophy heads that may be associated with the Wari culture, but they come from the hinterland—one in the Majes Valley (Tung, 2003) and the other from the Department of Cusco (Andrushko and Bellifemine, 2006; Tesar and Rao, 2007).

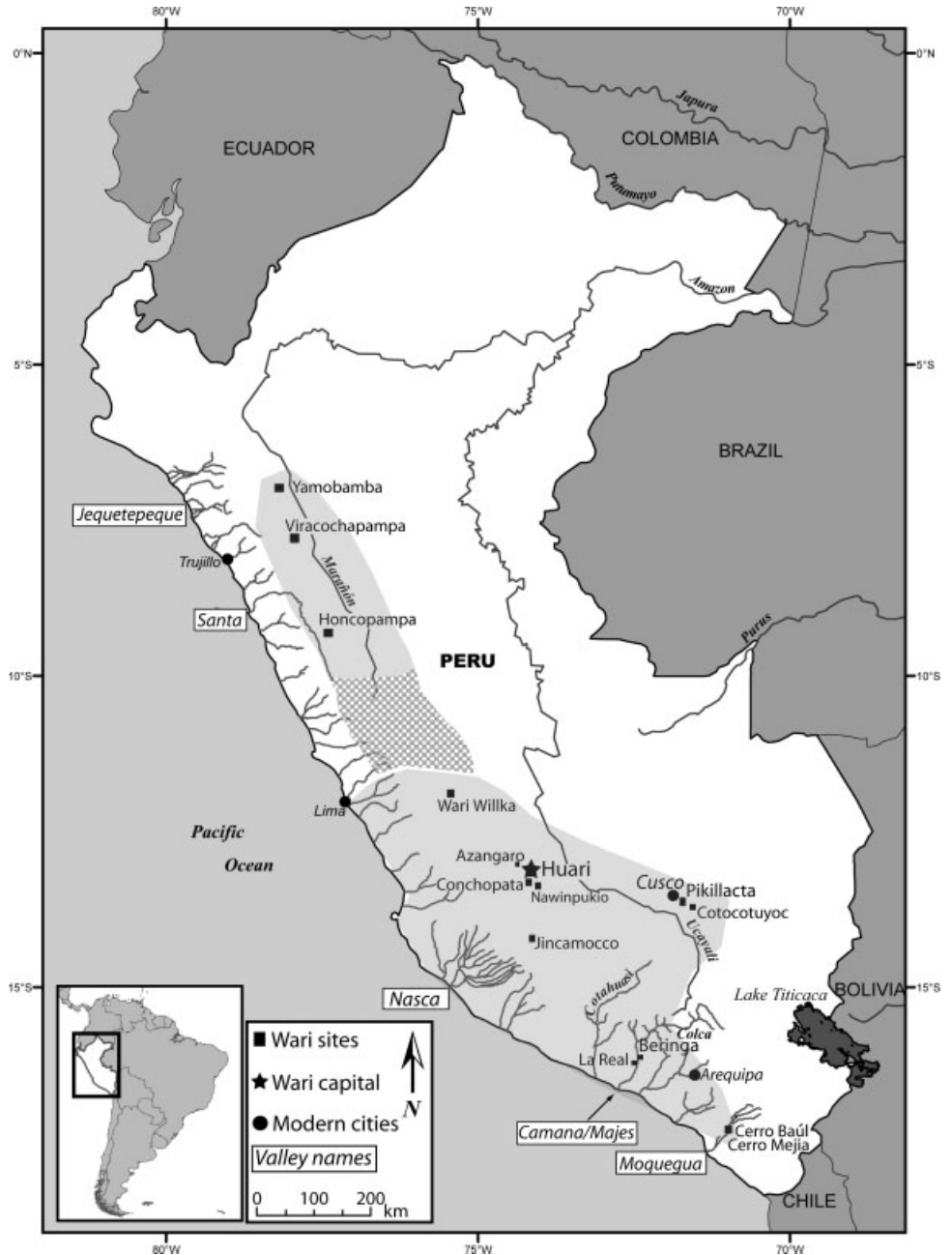


Fig. 1. Map of Peru showing several Wari sites and major valleys, some of which are discussed in the text. Areas shaded in gray show an estimate of the geographical extent of the Wari empire, which was likely a mosaic of control throughout the Peruvian Andes (Schreiber, 1992). The checker-board area has been little studied, so Wari's influence there has yet to be fully documented.

struct the identities of those who became trophy heads, this study presents data on age-at-death, sex, and morbidity, including cranial trauma, *cribra orbitalia*, and dental disease. These data aid in reconstructing their lived experience, which provide insights into the identities of those who were dismembered and modified into an object for ritual display.

TROPHY HEADS IN THE NEIGHBORING NASCA REGION

The Wari trophy heads described here are compared with those from the Nasca drainage, a neighboring region to the Wari heartland (see Fig. 1). The Nasca trophy heads are the most ubiquitous and well studied of

those from the Andes, thereby providing characteristics against which other Andean trophy heads can be compared (Proulx, 1971, 1989, 2001; Drusini and Baraybar, 1991; Browne et al., 1993; Verano, 1995, 2001; Williams et al., 2001; Kellner, 2002; Forgey and Williams, 2005).

A diagnostic trait of a Nasca trophy head is the hole drilled on the frontal bone through which a cord is threaded so it can be suspended for display (Verano, 1995) (see Fig. 2). The location and size of the hole on the frontal bone varies, as does the style of carrying cords. Holes may be between the orbits or much higher on the frontal bone, and the hole may be small and perfectly cylindrical, or large and irregularly shaped (see Fig. 2). Other modifications include an enlarged foramen magnum or removal of the entire cranial base to extract the brain (Verano, 1995) (see Fig. 2), and in some cases,

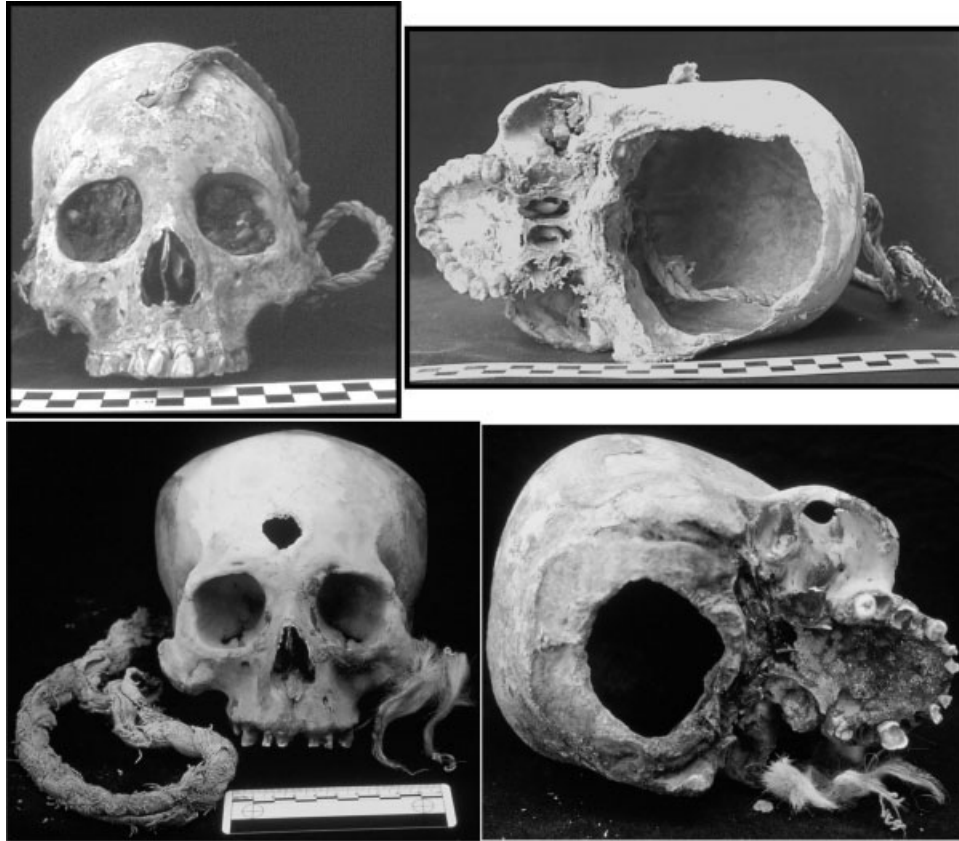


Fig. 2. Nasca style trophy heads.

the posterior half of the cranium and the cranial base is removed, creating a trophy head that resembles a mask (Kellner, 2002).

The Nasca culture (AD 1–700) precedes the Wari (AD 600–1000), and though Nasca communities were generally circumscribed within the Nasca drainage (see Fig. 1), Nasca iconography reached the highlands, influencing subsequent Wari iconography (Cook, 1994). Thus, it is likely that other Nasca cultural practices were integrated into Wari society. For example, the taking, modifying, and displaying of trophy heads by Nasca peoples were likely known by their highland neighbors to the east; perhaps aspects of these practices were adopted by the Wari.

As noted earlier, debates persist regarding the identity of persons who were transformed into trophy heads: were they heads of ancestors or enemies? Some scholars have proposed that Nasca trophy heads derive from deceased kin (biological or fictive) whose heads were altered postmortem for use as relics in ancestor veneration rituals (Neira Avendano and Coelho, 1972; Guillén, cited in Silverman 1993:p 224). In contrast, others have argued that the trophy heads derive from enemies encountered in wars, raids (Proulx, 1971, 1989, 2001; Verano, 1995, 2001), or ritual battles, known as *tinku* in the Andes (Browne et al., 1993; Silverman, 1993). The demographic profile of Nasca trophy head individuals shows that the majority are adult men, supporting the assertion that they may have been victims of raids or battles ('real' or ritual) (Verano, 1995). Moreover, iconography on a Nasca ceramic vessel shows a warrior decapitating a victim, further indicating that at least some tro-

phy heads derived from enemies, not revered ancestors (Verano, 1995; Proulx, 2001).

THE WARI EMPIRE AND THE SITE OF CONCHOPATA

The Wari empire, one of the first expansive empires in South America, originated in the central Andes of Peru, expanding from this highland locale to incorporate various populations from diverse geographical areas. There are Wari administrative and ritual centers throughout the Peruvian Andes (Isbell, 1989; Isbell and McEwan, 1991; Schreiber, 1992, 2001; Williams, 2001; McEwan, 2005), demonstrating a mosaic of control (Schreiber, 1992) (see Fig. 1). The Wari Empire incorporated the largest domain of any state-level society in the Andes until the rise of the Inka 400 years after its collapse. The Wari likely achieved this dominance through a mix of ideological indoctrination (Menzel, 1964) and military prowess (Lumbreras, 1974), as evidenced by ubiquitous iconography of warriors brandishing weaponry (Ochotoma and Cabrera, 2002) and cranial trauma frequencies of ~30% among several Wari populations (Tung, 2007b).

The isolated skulls that I identify as trophy heads come from the site of Conchopata, located in the Ayacucho Basin, 12 km south of the capital at Huari (see Fig. 1). It was the secondary site in the Wari heartland (Isbell and Cook, 2002), serving many functions from domestic to mortuary to ritual. More than 300 commingled human burials were recovered, mostly from under house floors, but no trophy heads were found in association with the mortuary remains (Tung, 2003).

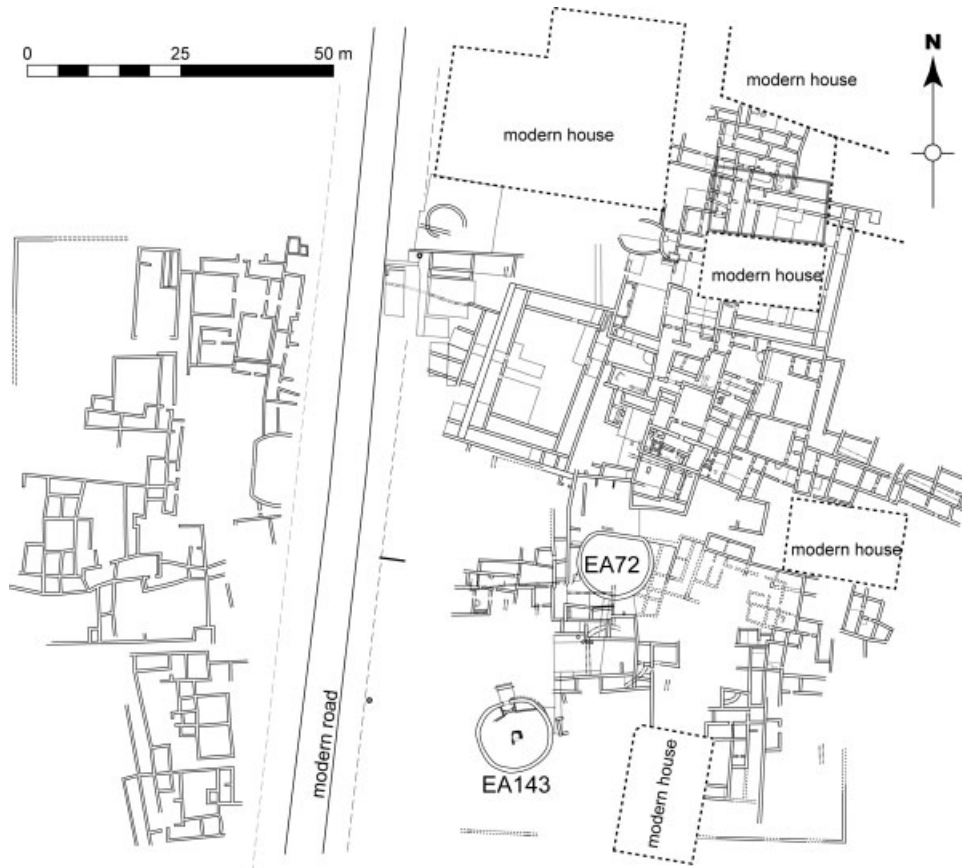


Fig. 3. Map of Conchopata. Trophy heads were recovered from EA72 and EA143 (Map by Juan Carlos Blacker).

Four ritual buildings—two circular and two D-shaped structures—attest to the importance of ritual in Wari society. The trophy heads come from two of these ritual spaces: EA72 and EA143 (see Fig. 3). No trophy heads have been recovered in any other rooms at the site.

Ritual context of the trophy heads

The *Proyecto de Excavaciones en un Poblado Alfarero de la Epoca Huari*, directed by Jose Ochatoma and Martha Cabrera, recovered commingled trophy heads from the southeast quadrant of a D-shaped room (EA72) (see Fig. 4). An intact, sacrificed camelid, a common component of Andean rituals in both the past and present, was placed directly above the trophy heads (Ochatoma and Cabrera, 2002). Additional camelid bones and large (1 m in diameter) ceramic urns that were intentionally smashed and deposited on the floor were excavated from the northern and western sections of this room. Several urns had elaborate iconography, showing warriors wearing trophy heads and carrying weapons and Wari deities dangling stylized trophy heads (Ochatoma and Cabrera, 2002; Ochatoma, 2007). These high quality artifacts, sacrificed camelids, and human trophy heads were clearly part of an elaborate ritual complex within Wari society.

The Conchopata Archaeology Project, directed by William Isbell and Anita Cook, recovered broken trophy heads from the southeast quadrant of a circular ritual room (EA143) (see Fig. 4). There were no ceramic sherds in direct association with the trophy heads, though some



Fig. 4. EA72 (D-shaped room) and EA143 (circular room). (Photos courtesy of Jose Ochatoma and William Isbell, respectively.)

fragments were found in upper strata and in other quadrants of the room. The only faunal bone in association with a trophy head was an incomplete ulna from a juvenile camelid, which had cutmarks on the proximal end; it was found with a child trophy head. Although there were no large, decorated ceramic urns or entire sacrificed camelids with these trophy heads, their presence in this elaborate ceremonial building attests to their ritual significance. Based on relative stratigraphic levels between the two structures and radiocarbon dates from surrounding rooms (Ketteiman, 2002), EA143 appears to predate EA72 (Tung and Cook, 2006).

MATERIALS AND METHODS

Because the trophy heads had been smashed on the floor of the ritual spaces, the crania and mandibles had to be reconstructed to calculate the minimum number of individuals in each ritual building. However, due to the commingled nature of the remains in EA72, the mandibles could not be associated with their respective crania. In this room (EA72), there were at least 10 trophy heads represented by 10 crania and 10 mandibles. The circular room (EA143) yielded a minimum of 21 trophy heads, not all of which were complete.

After the trophy heads were reconstructed, age-at-death and sex were estimated using guidelines from Buikstra and Ubelaker (1994). Age-at-death was estimated based on dental eruption (Ubelaker, 1989), dental wear (Scott, 1979; Smith, 1984), and cranial suture closure (Meindl and Lovejoy, 1985), whereas sex estimates for the adults were based on cranial morphology (Acsádi and Nemeskéri, 1970).

All ectocranial and endocranial bone surfaces were examined with a 10× handheld magnifying lens to detect cutmarks, chopmarks, intentionally drilled holes, and fractures. Following White (1992) and Andrushko et al. (2005), linear marks under 1 mm in width were identified as cutmarks, and those over 2 mm were identified as chopmarks.

If individuals who were transformed into trophy heads had engaged in battles or other forms of violence, then they should exhibit pre-mortem (healed) or perimortem cranial fractures; these may indicate that they belonged to a warrior class or, at the least, were expected to engage in physically risky fights (see Walker, 2001). Perimortem wounds, in particular, are strongly suggestive of violence (Lambert, 2002), and, in this context, may indicate a lethal battle to obtain the head. Head injuries may also be sustained in accidents (Lovell, 1997). Trophy heads with at least half of the calotte present were observed for trauma.

Documenting skeletal and dental lesions among individuals who were transformed into trophy heads provides insights into the disease experience of this unique subgroup and allows their health status to be compared with that of the Conchopata mortuary population and other groups. However, because only skulls are present, the pathological observations are limited to *cribra orbitalia*, a porous lesion that may be indicative of childhood iron deficiency anemia (Stuart-Macadam, 1985; Stuart-Macadam, 1987; Wapler et al., 2004) or deficiency of other nutrients resulting from inadequate nutritional uptake or excessive loss of nutrients from bacterial or viral infection (Walker, 1985; Ortner et al., 1999; Wapler et al., 2004). The orbital lesions may also result from inflammation caused by abscesses, sinusitis, or other

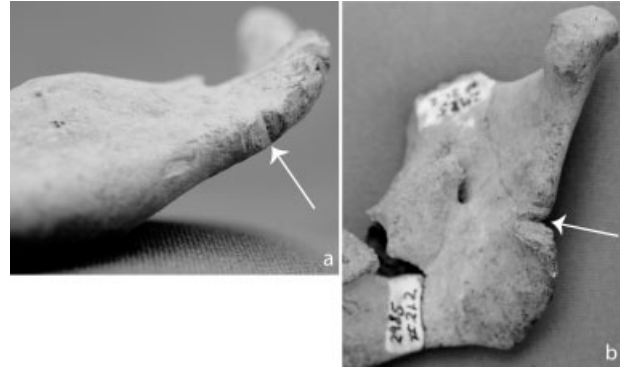


Fig. 5. (a) Chopmark on posterior-inferior edge of ascending ramus of a juvenile (EA143-P); (b) chopmark on inferior edge of ascending ramus of an adolescent (EA143-T).

nasal and oral diseases (Wapler et al., 2004). Dental disease is also examined, as this can provide insights into general oral health and dietary practices. (Oral health is the only link to diet at this time. The trophy heads were burned, leaving very little collagen or apatite in the bones; thus, carbon and nitrogen isotope analyses—a key method for dietary reconstruction—have not been conducted (Schoeninger, 1989; Ambrose and Katzenberg, 2000)).

RESULTS: ANTHROPOGENIC MODIFICATIONS

Perimortem damage, chopmarks, and cutmarks

Three cervical vertebrae were recovered from EA143, one of which was an axis. It does not exhibit cutmarks, but the dens has been broken off, and the surrounding area shows both perimortem and postmortem damage (see Fig. 5). The former may have occurred when the head was forcibly separated from the body, a necessary step in the creation of a trophy head when the body is fresh and intact (i.e., it has not yet decomposed to its skeletal form). It is unknown if decapitation was the mechanism of death or if the body was decapitated post-mortem.

Chopmarks are observed on 2 out of 22 mandibles. They are located on the posterior-inferior edge of the ascending ramus (near gonion) of a juvenile (EA143-P) (Fig. 6a) and on the posterior ascending ramus of an adolescent (EA143-T) (Fig. 6b). The shape and size of these marks are consistent with chopping or hacking with a heavily bladed tool or weapon (Walker and Long, 1977), and the locations of the chopmarks are consistent with decapitations in which the blow comes from behind (Waldron, 1996).

Cutmarks are present on the occipital bone, located lateral to the inferior nuchal lines on Trophy Head EA143-N (see Fig. 6) and on the mastoid process of EA143-I, suggesting that, in some cases, the posterior and lateral head/neck muscles were severed (e.g., rectus capitis posterior major and minor, sternocleidomastoid, and digastric). Cutmarks are also on one-third of the zygomatic bones (3/9 = 33%) and on half of the mandibles, along the posterior edge of the ascending ramus (11/22 = 50%). Given that the masseter muscle attaches to these two skull features, the cutmarks suggest that the masseter muscle was intentionally cut (Fig. 7a–c). Another mandible from EA72 exhibits a deep cutmark on the inferior edge of the mental eminence (Fig. 7d). Other cut-




Fig. 6. (a) Perimortem (and postmortem) damage to an axis; (b) cutmarks on the occipital bone, lateral to the inferior nuchal lines (EA143-N).

marks are observed along the left temporal line of trophy head EA143-K and on the anterior of the coronoid process of a mandible fragment from EA72. The temporalis muscle attaches at these two points, and although the cutmarks are on separate individuals, they suggest that the temporalis muscle may have been intentionally removed on some individuals.

Intentionally drilled perforations

Among the 26 Conchopata trophy heads with an observable calotte, 20 exhibit a hole at or within one centimeter of bregma (77%) (Figs. 8 and 9), and three others display a perforation in the center of the sagittal suture.² It is striking that 23 of the 26 (89%) exhibit a hole on the apex of the cranium, and more specifically, 20 out of 26 have a hole at or near bregma. A hole on the superior of the cranium allows it to be suspended with the face looking forward, a characteristic that appears to be an intentional engineering design. This precision and consistency, particularly in contrast to Nasca trophy heads with holes variably placed on the frontal bone, suggest that the process of preparing a Wari trophy head was standardized.

Holes were drilled on three-quarters of the occipital bones (6/8 = 75%). The two occipital bones from EA72

²Small fragments of bone with portions of a drilled hole were recovered from the other five trophy heads, but it is unknown exactly where on the cranium the hole was located. In some cases, the hole is clearly along the coronal suture, but unclear if it is in the center, at bregma. For this reason, they are considered unobservable and excluded from the analysis of hole location.

exhibit one hole each on the cruciform eminence (Fig. 10a,b), and the four occipitals with holes from EA143 have one or two perforations each (Fig. 10c,d).³ Although the location of the hole on the occipital bones differs between the ritual structures, the function of the hole was likely the same. They were probably conduits for a carrying cord, perhaps to suspend the entire trophy head or to display the occipital bones as separate trophies after they were detached from the skull. In support of the latter, two occipital bones were found together on the floor of the circular ritual room. A partial cranium was deposited near the occipital bones, but it is unknown if it goes with one of the occipitals. (Tiny fragments were missing, and parts of the cranium were warped from burning, factors that prevented me from mending it to one of the occipitals.) If the incomplete cranium goes with one of the occipital bones, there still remains one isolated occipital that may have been used as a trophy or amulet. The isolated occipital bones also exhibit a patina on the edges, suggesting that they were frequently handled, as would be expected with amulets.

Among the 16 mandibles with at least one ascending ramus, three exhibit an intentionally drilled hole, two of which were complete and exhibit perforations on both rami (see Fig. 11). It is unknown if the third mandible had holes on both sides, as only the left side was present. All three individuals—a child, an adolescent, and an adult—are from EA143. The perforations on the ramus and the intentionally severed masseter muscle (described earlier) indicate that, on occasion, mandibles may have been displayed solo or tied back to the cranium. Verano (2001; Fig. 8.4) suggests that the latter was done with a Moche skull bowl that similarly had holes on the ascending ramus. Some Nasca trophy heads also have reattached mandibles, but they were reattached by wrapping cordage around the ascending ramus and tying it to the zygomatic bone (Verano, 1995).

The average diameter of perforations on the superior of the cranium equals 12 mm (SD = 2.84 mm, $N = 23$), and the diameter of occipital holes averages 6.2 mm (SD = 2.01, $N = 7$ because some occipitals had two measurable holes). The average diameter of measurable holes on the ramus equals 4.94 mm (SD = 1.89, $N = 4$). One-way analysis of variance (ANOVA) of hole diameter at each of the three skull locations shows the differences to be statistically significant ($F = 21.60$; $df = 2, 33$; $P < 0.001$). These perforations were likely made with chert drills, several of which have been recovered from Conchopata (Bencic, 2000).

Dismemberment of phalanges

Eighty-four hand phalanges and 17 foot phalanges (proximal, intermediate, and distal) were recovered from the circular ritual structure (EA143), but no metacarpals, carpals, metatarsals, or tarsals were present. Given that all three parts of the phalanges were present, it appears that whole fingers and toes were brought into the ritual space. Four proximal hand phalanges exhibit cutmarks and damage on the base of the dorsal surface, and one proximal hand phalanx (thumb) shows cutmarks on the base and midsection of the palmar surface (see

³Two of the EA143 occipitals were incomplete, so only one hole was observed on each. Each hole was on the lateral portion; presumably, a second hole would have been present on the opposite lateral side, like the others from EA143 (Fig. 10c,d).

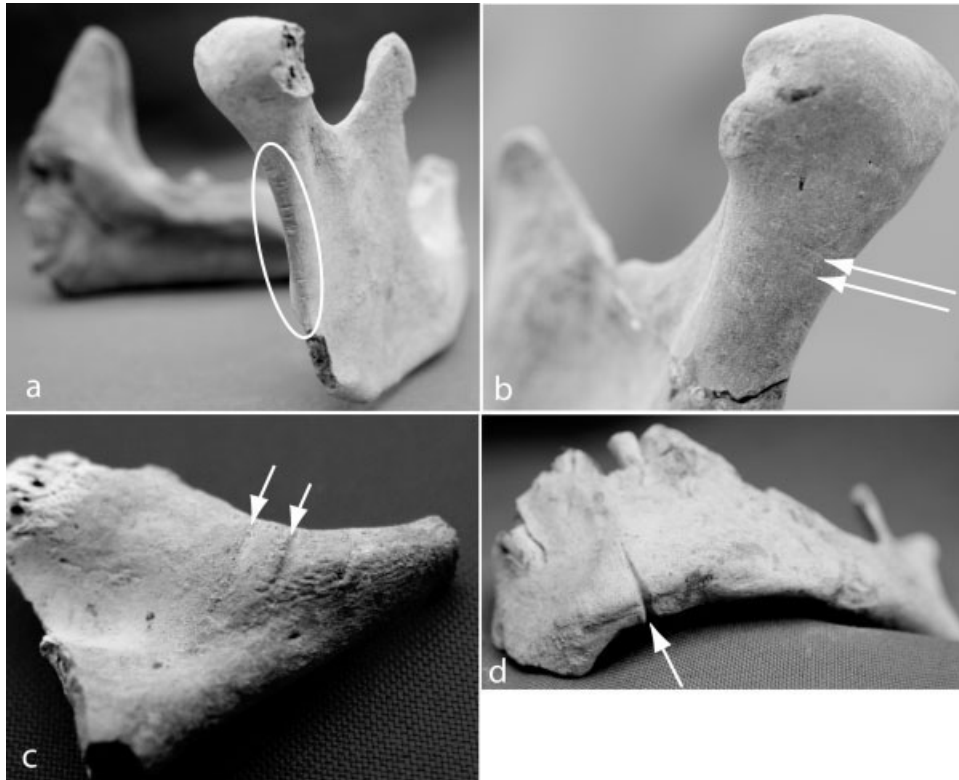


Fig. 7. (a and b) Cutmarks on the posterior edge of the ascending ramus; (c) cutmarks on the inferior margin of a zygomatic bone; (d) cutmark on the inferior edge of the mental eminence.

Fig. 12). These cutmarks suggest that fingers may have been cut off at the knuckles while soft tissue was still attached. It is unknown if the person was alive or recently deceased when the fingers were removed or if an isolated fleshed hand was further processed by cutting off the fingers. One hand phalanx exhibits an apparent hole drilled through the length of the shaft, suggesting that it may have been strung on a cord to suspend it as a trophy or amulet (see Fig. 12).

Burned trophy heads

Twenty-eight of the 31 trophy heads (90%) were completely burned, likely at high temperatures exceeding 800°C, as evidenced by their grayish-white color and vitrification that gave them a consistency similar to glass (Walker et al., 2008). The three exceptions include two skulls with no heat exposure whatsoever, and a third that was only partially burned when soft tissue was still present. This is evidenced by burn patterns showing that the temporalis muscles were covering the sides of the skull, protecting those areas from burning (Fig. 8c). This suggests that this particular trophy head may have been initially displayed when soft tissue and even facial features, were still visible.

RESULTS: DEMOGRAPHY AND HEALTH

Age and sex of the trophy head individuals

Among the 31 trophy heads, 24 are adolescents/adults (77%), and 7 are children (23%) (Table 1). Although it has been reported that a trophy head from a “dwarf individual” was present in the D-shaped structure (Ochotoma and Cabrera, 2002, p 235), my osteological analysis shows that it was instead a juvenile. Of the 17 adults whose sex could be determined, males are significantly

more common (88%) than females (12%) relative to an equal distribution (Fisher’s exact, $P = 0.018$). This suggests that adult males may have been targeted for transformation into trophy heads. That is, they did not randomly select corpses or living persons for this unique processing.

Trophy head trauma

Of the 19 adult trophy heads observable for trauma, eight were affected (42%), all of whom were male, suggesting that violence, or in some cases accidental injury, was common among those who were made into trophy heads. Of those eight with head wounds, one of them exhibits a perimortem fracture, indicating that the injury was sustained around the time of death (Fig. 13b). The other seven exhibit well-healed wounds, indicating nonlethal violence earlier in the person’s life (Fig. 13a). Four of the wounds are on the anterior of the skull, suggesting face-to-face conflicts, while the other four are on the posterior, perhaps suggesting that some were injured while fleeing during raids (see Walker, 1997). Although some of the injuries may have been accidental, the circular depression fractures are consistent with mace and sling stone injuries, and the spatial distribution of the head wounds parallels that observed in other Wari groups (mostly anterior and posterior head wounds), where violence is the likely explanation (Tung, 2007b).

The trophy head trauma frequency (42%), however, is not significantly different from that of the domestic adult burial population (nontrophy heads) at Conchopata (10/44 = 23%) (Fisher’s exact, $P = 0.105$; $N = 63$) or adults from Wari affiliated sites in the Majes valley (45/143 = 32%) (Tung, 2007b) (Fisher’s exact, $P = 0.248$; $N = 162$). This suggests that the trophy head and nontrophy head

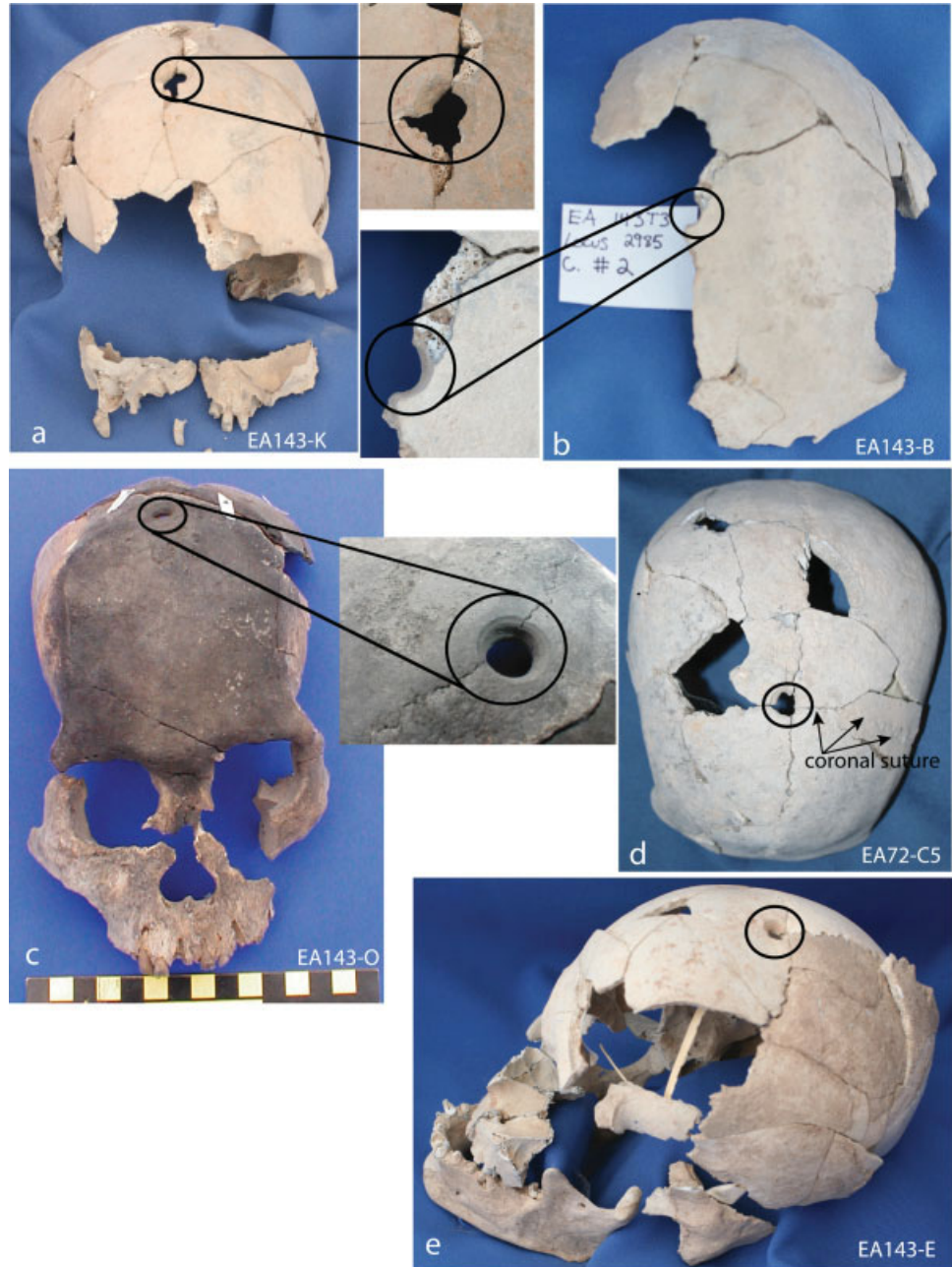

Fig. 8. (a) Old adult male with hole at bregma; (b) Old adult (probable male) with hole slightly posterior to bregma; (c) mid-adult male with hole at bregma and burn patterns indicating temporalis muscles were present when it was burned; (d) Mid-adult male with hole at bregma; (e) mid-adult male with hole at bregma and on the ascending ramus. Note that all, except EA143-O, are grayish-white from high temperature (>800°C) burning. [Color figure can be viewed in the online issue, which is available at www.interscience.wiley.com.]

subpopulations may have had similar lifestyles, inasmuch as violence was concerned.

Morbidity profile of the trophy head individuals

One of 17 adults with observable orbital roofs exhibits *cribra orbitalia* (6%) (Table 1). Oral disease, in contrast, was more common. Of the 18 adults with at least five observable mandibular sockets, 22% exhibit an abscess (4/18 = 22%), and 56% experienced premortem tooth loss (10/18 = 56%). Because the trophy heads had been smashed and burned, only seven adults with at least two well preserved mandibular teeth could be observed for dental caries; two of them were affected (2/7 adults = 29%). These seven adults have a total of 23 observable teeth (2/23 teeth = 9%).

DISCUSSION

Possible decapitation

The chopmarks on the mandible and the perimortem damage on the axis suggest that some individuals may have been decapitated (see Waldron, 1996). A blow from behind with a heavy, sharp weapon, such as a large obsidian or chert axe like those recovered from Conchopata (Bencic, Personal Communication, 2007), can leave chopmarks that are perpendicular to the posterior and inferior edges of the ramus. Alas, these marks do not reveal whether decapitation was the mechanism of death or if the beheading was done postmortem to make a trophy head. Among other prehispanic Andean groups with isolated skulls and trophy heads, such as the Moche and Nasca, artistic works depict individuals beheading pre-

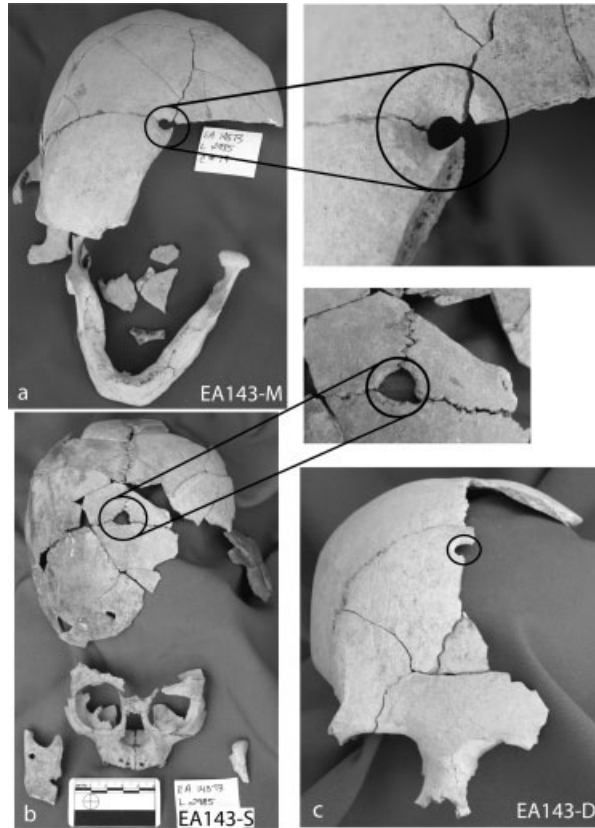


Fig. 9. (a) Old adult male with hole at bregma and premortem tooth loss; (b) child with hole at bregma and the ascending ramus; (c) mid-adult (probable female) with hole slightly anterior to bregma.

sumably living people, which strongly suggests that lethal decapitation was used in the production of trophy heads (Verano, 1995; Cordy-Collins, 2001; Proulx, 2001). To my knowledge, there are no images or figurines of Wari individuals or deities in the act of beheading a live person. But, there is iconography on an oversized urn from a ritual deposit of broken pottery at Conchopata that shows the Front Face Deity holding a bound prisoner, while to its immediate right the Winged Profile Sacrificer (Cook, Personal Communication, 2006) dangles a fleshed trophy head (Isbell and Cook, 2002) (see Fig. 14). (I suggest that the white tubular object dangling from the base of the trophy head is the trachea, further evidence that fresh heads were processed.) Although it is unclear what the relationship is between the bound captive and trophy head (i.e., is it recounting an event where captives are eventually decapitated and transformed into trophy heads?), their side-by-side depiction on a ritually smashed urn provides compelling evidence that they are closely related events.

Dismembering and mutilating fresh bodies, not old corpses

Although lethal decapitation cannot be unequivocally demonstrated, the skeletal data demonstrate that fresh bodies were dismembered so certain body parts could be used as trophies. The cutmarks on the mandibles, zygomatic bones, temporals, and occipital—evidence that soft tissue had to be removed—suggest that recently deceased persons were transformed into trophy heads. The processing of heads likely began shortly after death, not years postmortem, indicating that skulls were not taken from old corpses. Similarly, the isolated hand and foot phalanges and the cutmarks on the proximal hand pha-

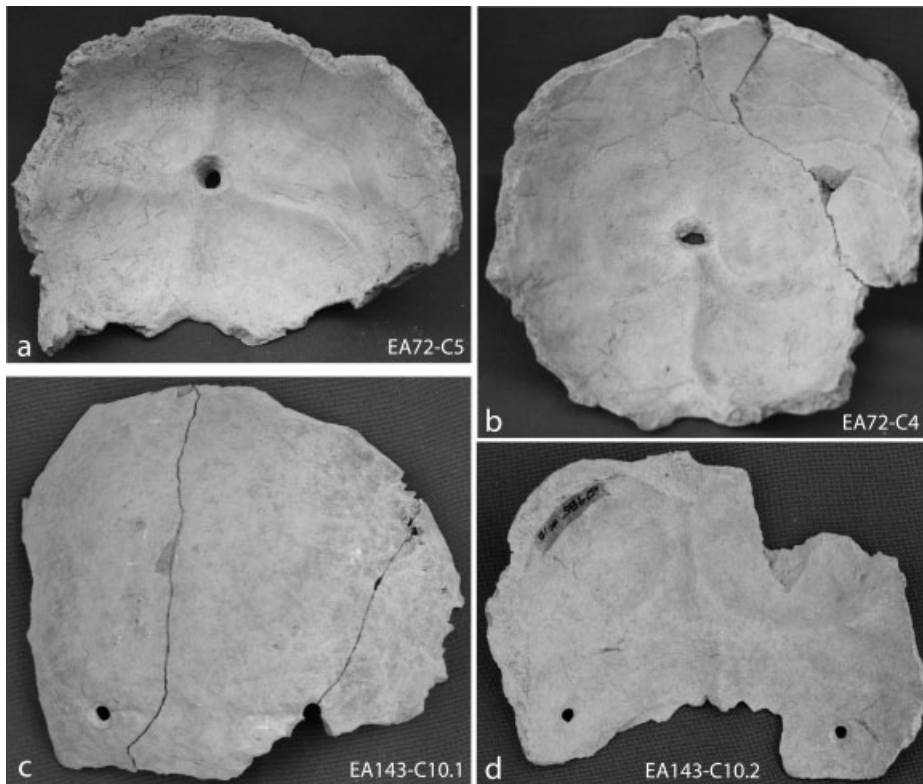


Fig. 10. (a and b) endocranial view of a single hole on the cruciform eminence of the occipital bone; (c) ectocranial view of two holes on the occipital bone, near the inferior nuchal line; (d) two holes on the occipital bone; from this endocranial view, the holes can be seen inferior to the transverse sulci.

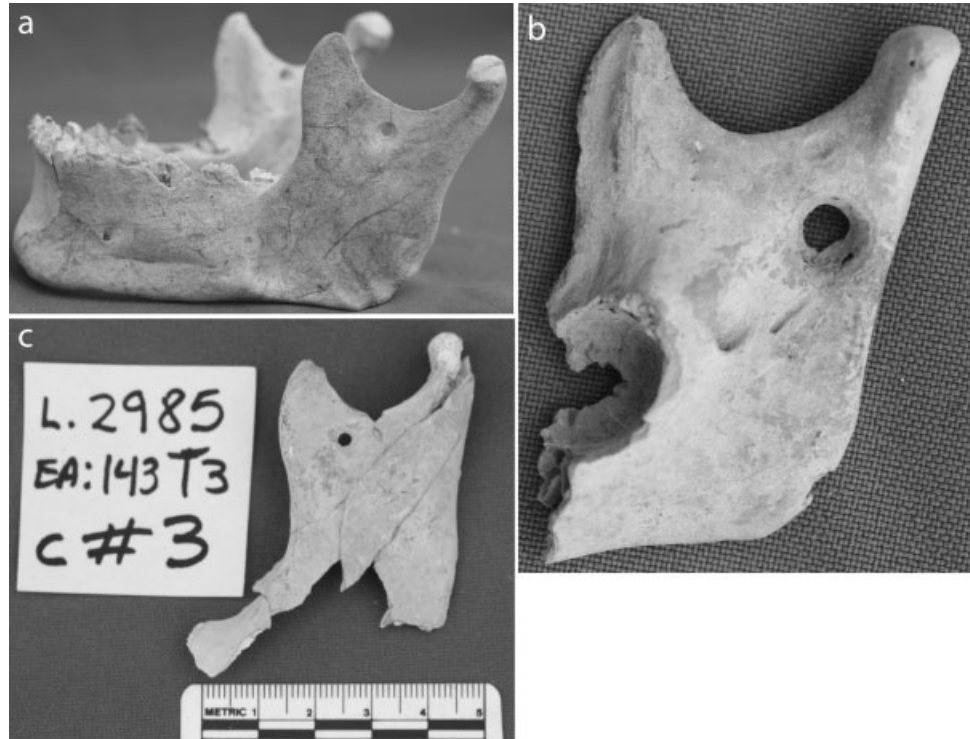


Fig. 11. (a) Holes on left and right ascending ramus of a mandible from mid-adult male (EA143-E); (b) medial view of a hole on the right ascending ramus of a child mandible (EA143-S); (c) lateral view of a hole on the left ascending ramus of an adolescent mandible (EA143-C).

langes suggest that bodies were mutilated around the time of death, cutting off fingers (and probably toes) to retain them as trophies.

Similarly modified Wari trophy heads in the same ritual spaces

The similarly modified trophy heads, the matching representations of them in art, and their circumscribed distribution at the site suggest that their preparation and use was tightly controlled. They exhibit similarly sized, well-drilled holes on the apex of the cranium, which is in contrast to Nasca trophy heads that show variably placed holes of different sizes somewhere along the midline of the frontal bone. Granted, the Nasca trophy heads studied thus far derive from a variety of sites and time periods; nonetheless, when temporally or spatially contemporaneous Nasca trophy heads are compared, their modifications are not nearly as standardized as Wari trophy heads (see Drusini and Baraybar, 1991; Browne et al., 1993; Williams et al., 2001; Kellner, 2002). Nasca trophy heads also vary from complete heads to facial masks, whereas Wari trophy heads and artistic depictions of them are notably alike. For example, Wari images depict warriors wearing trophy heads around their necks such that the trophy head faces forward as it dangles (see Ochatoma and Cabrera, 2002). This coincides with the actual modified skulls that show a hole on the apex, a design trait that ensures it is displayed facing anteriorly. Additionally, given that all trophy heads come from only two ritual structures, their use and display appears to have been managed closely. This likely ensured that trophy heads served as a stable and powerful material reminder of the authority of the Wari state and its agents, demonstrating their ability to capture bodies, dismember and display them in specified ways, and put them to ritual use in highly structured contexts.

This level of coordination and standardization may suggest that there was state oversight regulating how these heads should be processed, depicted in art, and incorporated into rituals.

Two Wari trophy heads in the hinterlands

A single trophy head from a Wari affiliated site, Cotoctuyoc in Cusco, is quite distinct from the Conchopata trophy heads. It does not exhibit a hole on the apex of the cranium or on the occipital bone. Rather, it shows a large circular perforation (24.88 mm) at lambda, a smaller one (5.01 mm) superior to that, and several tiny holes (1 mm) along the sides of the cranium, some of which are plugged with gold alloy tacks (Andrushko and Bellifemine, 2006; Tesar and Rao, 2007) (specific measurements from Andrushko, Personal Communication, 2007). Its uniqueness suggests that the local population did not fully adopt the Wari heartland style of trophy heads. A trophy head from the Majes valley, in contrast, exhibits the telltale Wari trophy head trait—an intentionally drilled hole at bregma (Tung, 2003). Although it is unknown if the trophy head individual is from the local area, the Wari heartland, or elsewhere, its presence may suggest that Wari influence in the ritual realm was quite strong in this southern region.

Possible raiding for trophy heads: men and children favored

The demographic profile of the Wari trophy heads shows that adult men were preferred as trophies, followed by children. Women were the least likely to be transformed into a trophy head. This unbalanced sex profile mirrors that of the Nasca trophy heads (see Verano, 1995), where 92% are male (90/98) and 8% are female (8/98) (Tung, 2007a). The male biased sex distri-

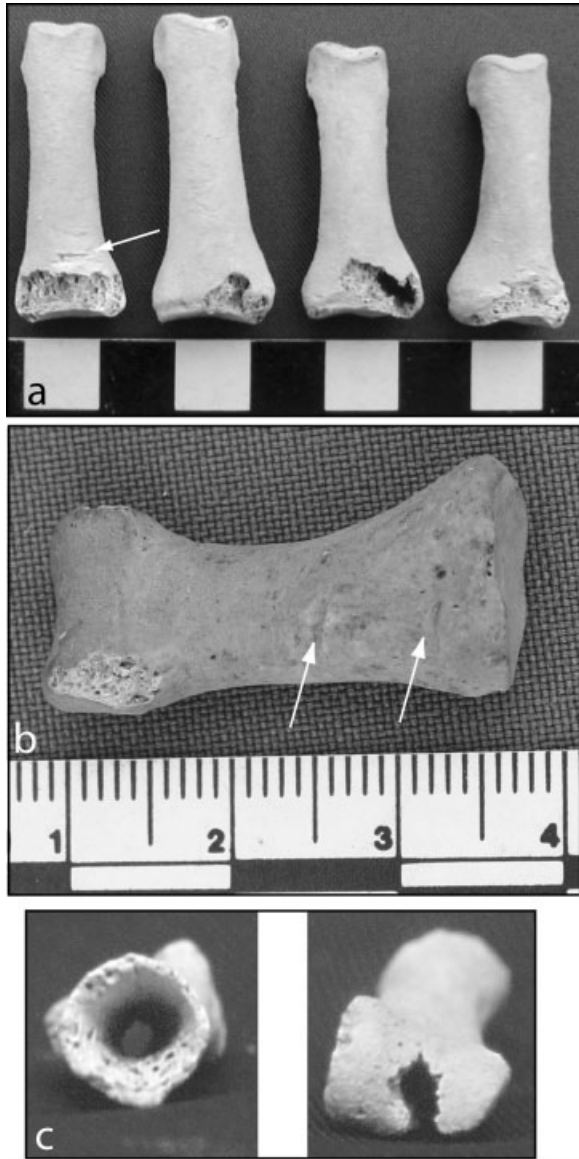


Fig. 12. (a) Cutmark and possible perimortem damage on dorsal aspect of proximal hand phalanges; (b) cutmarks on palmar surface of proximal hand phalanx 1 (thumb); (c) possible drilled hole along length of hand phalanx.

bution among Nasca trophy heads has been interpreted as evidence that they were obtained in warfare (Proulx, 1989, 2001; Verano, 1995); perhaps, Wari trophy heads from men were similarly acquired. On the one hand, their high percentage of trauma (42%) suggests that they engaged in violent conflicts, as expected for warriors engaged in warfare. On the other hand, the frequency is statistically similar to other Wari affiliated populations, so it is possible that these were commoner men, not warriors, who occasionally fought, perhaps during raids on their community. This would suggest that trophy head victims were similar to many other men within parts of the Wari domain who were at high risk for violent encounters, either in the context of battles, physical conflict resolutions, or raids (Tung, 2007b).

Raids on villages inhabited by families may have been a key method for obtaining captives (or heads) for even-

tual trophy head transformation, an activity that seems all the more likely given the number of child trophy heads. By comparison, the frequency of Wari child trophy heads ($7/31 = 23\%$) is statistically significantly higher than those from Nasca ($9/123 = 7\%$) (Fisher's exact, $P = 0.021$; $N = 154$) (Tung, 2007a), suggesting that Wari head taking occurred in contexts where children were present. Raids on villages are one such context: battlefields are not. Thus, it may be that Nasca trophy heads were created from male victims primarily taken in battle (Verano, 1995; Proulx, 2001), while Wari ones were made from men and children, and occasionally women, likely taken in raids. This, of course, does not exclude the possibility that Wari warriors sometimes captured men or men's heads in battles. The salient point here is that the high number of child trophy heads indicates that battles were not the exclusive source; raids may account for how some were acquired. Based on osteological data alone, it is unclear if live individuals were taken captive or if only their heads (and fingers and toes) were taken at the conflict site. The iconographic data suggest that the former was done by Wari military personnel, but does not exclude the possibility that they occasionally took only body parts.

This phenomenon where all age and sex classes are targeted in violent acts is known as "social substitutability" (Kelly, 2000). During conflicts, any individual from the enemy group may be victimized—man, woman, or child—because violence against one is perceived as injury to the entire group. In this way, raids by Wari military personnel in which they captured people, or at least their body parts, likely served as potent symbols of dominance over other communities.

Killing offspring of real and perceived enemies also may have been a Wari strategy to maintain control, particularly if the children were offspring of local elites. This kind of strategy has long been employed by ruling or aspiring ruling groups from ancient Chinese dynasties to the Bolsheviks during the Russian revolution (Pipes, 1991).

Although it is possible that heads were taken from either naturally deceased or sacrificed individuals from Conchopata, this seems unlikely given the iconography described earlier showing a bound captive and a trophy head together on a ritual urn (see Fig. 14). Furthermore, the perimortem cranial fracture on an adult male, some of the best evidence for violence (Lambert, 2002), suggests that there was a lethal battle to obtain the head of this apparent foe. Although the trauma and iconographic data may also characterize a judicial killing of a criminal, the ubiquitous military iconography contradicts that, but does not wholly eliminate it as a possibility.

Disease experience of the trophy head victims

The low *cribra orbitalia* frequency (6%) of the trophy head victims is similar to that of adults buried in the Wari era mortuary spaces at Conchopata ($1/31 = 3\%$) (Tung, 2003) and among adults at Wari era sites in the Nasca valley ($4/77 = 5\%$) (Kellner, 2002) and Majes valley ($19/86 = 22\%$) (Tung, 2003) (trophy head adults vs. Majes valley adults, Fisher's exact, $P = 0.108$, $N = 103$). It is also similar to all age groups from multiple time periods in the Cuzco region ($18/495 = 4\%$) (Andrushko, 2007). In contrast, the adult Wari trophy heads show significantly lower percentages of the lesion relative to people from the contemporaneous Tiwanaku affiliated site of

TABLE 1. Age-at-death, sex, and pathological observations of the Conchopata trophy heads

Code ^a	Age category ^b	Sex	Cribra orbitalia	Cranial trauma
EA143-A (#1)	Child	?	?	No
EA143-B (#2)	Old adult	M?	No	No
EA143-C (#3)	Adolescent	?	No	No
EA143-D (#4)	Mid-adult	F?	No	No
EA143-E (#5)	Mid-adult	M	Yes	No
EA143-F (#6)	Mid-adult	M	No	No
EA143-G (#7.01, 16)	Young adult	?	No	No
EA143-H (#14, 15)	Child	?	?	?
EA143-I (#7.02)	Young adult	M	No	No
EA143-J (#9)	Mid-adult	M	No	Yes
EA143-K (#10.01)	Old adult	M	No	Yes
EA143-L (#10.02)	Mid-adult	?	?	?
EA143-M (#17)	Old adult	M	?	Yes
EA143-N (#11)	Old adult	M	?	No
EA143-O (#12.01, 12.02)	Mid-adult	M	No	Yes
EA143-P (#13, 14.02)	Child	?	No	No
EA143-Q (#15, 8)	Young adult	M	No	No
EA143-R (#18.01)	Young adult	M	?	Yes
EA143-S (#19)	Child	?	No	?
EA143-T (#21.01, 21.02)	Adolescent	M	No	?
EA143-U (#21.01, 21.02)	Adult	?	?	?
EA143-12.01	Not a separate person, but unclear with whom this cranial fragment is associated			
EA143-18.02	Not a separate person, but unclear with whom this cranial fragment is associated			
EA143-20	Not a separate person, but unclear with whom this cranial fragment is associated			
EA72-C1	Child	?	?	No
EA72-C2	Child	?	No	?
EA72-C3	Mid-adult	M	No	Yes
EA72-C4	Adult	M	No	Yes
EA72-C5	Mid-adult	M	No	Yes
EA72-C6	Adolescent	?	?	No
EA72-C7	Young adult	?	No	No
EA72-C8	Adolescent	?	No	No
EA72-C9	Young adult	?	?	No
EA72-C10	Child	?	Yes	?

^aThe letters after EA143 are the lab codes, and the numerals in parentheses are the cranial cluster codes assigned by the archaeologists when the bones were found *in situ*.

^bChild = 3–12 years; Adolescent = 13–19 years; Young adult = 20–34 years; Mid-adult = 35–49 years; Old adult = 50+ years; Adult = 20+ years.

Chen Chen (60/165 = 36%) (Blom et al., 2004) (Fisher's exact, $P = 0.007$) and Middle Horizon/Late Intermediate Period Chiribaya sites (126/292 = 43%) (Burgess, 1999) (Fisher's exact, $P < 0.005$), all located in the Moquegua valley of southern Peru. Thus, in terms of iron or other nutritional deficiencies or inflammatory infections, the adults whose heads ended up on the floors of Conchopata's ritual structures are similar to adults within the Wari sphere that have thus far been examined, but quite distinct from those from Tiwanaku affiliated sites in southern Peru.

The high frequencies of dental abscesses and tooth loss suggest that these individuals suffered poor dental health, perhaps caused by consumption of cariogenic foods, such as maize and other carbohydrates. Their dental health is similar to the Wari affiliated commoner village at Beringa, in the Majes valley, where 44% of adults suffered from dental caries, 30% had dental abscesses, and 58% experienced premortem tooth loss (Tung and Del Castillo, 2005). In contrast, the elite, Wari affiliated site of La Real, also in the Majes valley, had much lower frequencies of caries (2/19 = 10.5%) and abscesses (2/39 = 5%) (Tung and Del Castillo, 2005). Although the trophy head dental sample is small, these data tentatively suggest that those who were selected for trophy head transformation suffered from dental disease in a manner

more similar to hinterland commoners than hinterland elites.

These paleopathological results showing both similarities and differences in health between the trophy head group and other populations makes it unclear from what region trophy head victims may have been taken. Perhaps the trophy head victims derive from both local and distant areas to the Wari heartland. Indeed, preliminary strontium isotope analysis of five trophy heads and six local Conchopata burials suggests that at least three of the trophy heads come from a geological region distinct from the Ayacucho Basin (Tung, 2003; Tung and Knudson, 2006). This suggests that at least some may have been from foreign locales, increasing the likelihood that some trophy head victims were enemies.

CONCLUSION

The skeletal evidence obtained from the trophy heads not only reveals details about their health status when alive and how the bones were modified after death, these data also provide insights into Wari society and aspects of the Wari state apparatus. The specific modifications to the trophy heads, which required resources, time, and skill, and the ritual context in which the trophy heads

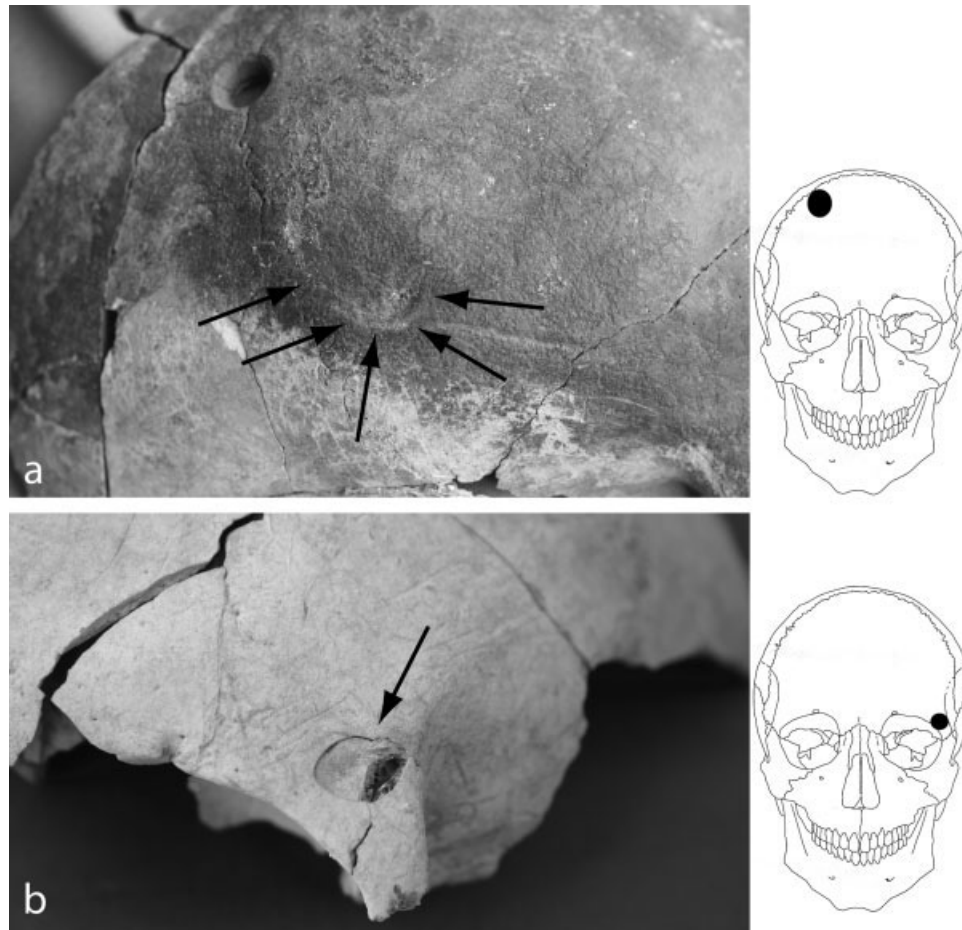


Fig. 13. (a) Premortem (healed) trauma on mid-adult male (EA143-O); (b) perimortem trauma on adult male (EA72-C4).




Fig. 14. Polychrome design on an oversized urn (Isbell and Cook, 2002) showing the Front Faced Deity dangling a captive with hands bound behind the back and the Winged Profile Sacrificer holding a fleshed trophy head, possibly with the trachea still intact. (Photo courtesy of William Isbell.)

were found, demonstrate that this Wari community viewed them as powerful relics worthy of elaborate treatment and display. It is also apparent that these objects were fashioned from recently deceased persons, not old,

decomposed corpses, which suggest that ancestral corpses of the Conchopata population likely were not used as trophies. Although the trophy heads could have been made from recently deceased local people, the iconography showing live, human prisoners and fleshed trophy heads together on the same ceramic urn (Isbell and Cook, 2002; Ochatoma and Cabrera, 2002) suggests that some of the trophy head individuals may have been perceived as enemies.

The standardized anthropogenic modifications of the trophy heads, as well as the matching artistic depictions of them on state-produced ceramics,⁴ suggest that there was state oversight that attempted to ensure uniformity in how these bodies were processed and presented in ritual arenas. Although there are some subtle variations, perhaps reflecting individual agency of the person(s) who

⁴There are large kilns at the site, and the ceramic ritual urns with trophy heads depicted on them are huge (1 m in diameter) with fancy polychrome images and designs, suggesting that they were not made at the household level. Rather, attached specialists/master craftspeople likely produced them under the auspices and direction of the Wari state (see Cook and Benico, 2002; Isbell and Cook, 2002). The creation of trophy heads appear to have been a part of this state production system given that they are elaborately and accurately depicted on the state-produced urns.

prepared them (see Brumfiel, 1996 and Tung and Cook, 2006), the overall similarities may reflect a state system that was coordinated to convey Wari authority through overtly physical and visual means. These aggressive and demonstrative acts—the capture, dismemberment, and display of human body parts—also would have helped to create and maintain the authority of Wari political elites. In this way, trophy heads were not merely props in rituals. The heads themselves and what they symbolized likely extended outside of the ritual arena, serving to develop and shore up Wari authority in social and political realms. Ultimately, head taking and their display combined with other tactics, such as military might, control of trade routes, and resource dominance, may have enabled Wari leaders to incorporate diverse groups of Andean people into the Wari empire.

ACKNOWLEDGMENTS

I thank William Isbell, Anita Cook, Jose Ochatoma, and Martha Cabrera for permitting me to study the Conchopata trophy heads, and I thank John Verano and Valerie Andrushko for several very informative discussions on trophy heads in the Americas. Andrushko also provided helpful, specific comments on the manuscript, for which I am grateful. Finally, I thank the associate editor, Lori Wright, the editor, Christopher Ruff, and the anonymous reviewers for their insightful comments on my manuscript.

LITERATURE CITED

- Acsádi GY, Nemeskéri J. 1970. History of human life span. Budapest: Akadémiai Kiadó.
- Ambrose SH, Katzenberg MA. 2000. Biogeochemical approaches in paleodietary analysis. New York: Kluwer Academic/Plenum Publishers.
- Andrushko VA. 2007. The bioarchaeology of Inca imperialism in the heartland: an analysis of prehistoric burials from the Cuzco region of Peru. Ph.D. dissertation. Santa Barbara: University of California.
- Andrushko VA, Bellifemine V. 2006. Descripción de restos óseos humanos de los contextos funerarios de Cotocotuyoc. Report submitted to the Instituto Nacional de Cultura-Cusco.
- Andrushko VA, Latham KAS, Grady DL, Pastron AG, Walker PL. 2005. Bioarchaeological evidence for trophy-taking in prehistoric central California. *Am J Phys Anthropol* 127:375–384.
- Bencic CM. 2000. Industrias líticas de Huari y Tiwanaku. In: Kaulike P, Isbell HW, editors. *Boletín de arqueología PUCP, Huari y Tiwanaku: modelos vs. evidencias*. Lima: Fondo Editorial de la Pontificia Universidad Católica del Perú. p 89–118.
- Blom DE, Buikstra JE, Keng L, Tomczak P, Shoreman E, Stevens-Tuttle D. 2004. Anemia and childhood mortality: latitudinal patterning along the coast of Pre-Columbian Peru. *Am J Phys Anthropol* 2:152–169.
- Browne DM, Silverman H, García R. 1993. A cache of 48 Nasca trophy heads from Cerro Carapo, Peru. *Lat Am Antiq* 4:274–294.
- Brumfiel EM. 1996. Figurines and the Aztec state: testing the effectiveness of ideological domination. In: Wright RP, editor. *Gender and archaeology*. Philadelphia: University of Pennsylvania Press. p 1431–166.
- Buikstra JE, Ubelaker DH. 1994. Standards for data collection from human skeletal remains. Fayetteville: Arkansas Archaeological Survey.
- Burgess SD. 1999. Chiribayan skeletal pathology on the south coast of Peru: patterns of production and consumption. Ph.D. dissertation. Chicago: University of Chicago.
- Cook AG. 1994. Wari y Tiwanaku: entre el estilo y la imagen. Lima, Peru: Pontificia Universidad Católica del Perú.
- Cook AG. 2001. Huari D-shaped structures, sacrificial offerings, and divine rulership. In: Benson EP, Cook AG, editors. *Ritual sacrifice in ancient Peru*. Austin: University of Texas Press, p 137–163.
- Cook AG, Benco N. 2002. Vasijas para la fiesta y la fama: producción artesanal en un centro urbano Wari. In: Kaulicke P, Isbell WH, editors. *Boletín de arqueología PUCP: Wari y Tiwanaku: modelos y evidencias*. Lima: Fondo editorial, Pontificia Universidad Católica del Perú. p 489–504.
- Cordy-Collins A. 2001. Decapitation in Cuspisnique and early Moche societies. In: Benson EP, Cook AG, editors. *Ritual sacrifice in ancient Peru*. Austin: University of Texas Press, p 21–34.
- Drusini AG, Baraybar JP. 1991. Anthropological study of Nasca trophy heads. *Homo* 41:251–265.
- Forgey K, Williams SR. 2005. Were Nasca trophy heads war trophies or revered ancestors? Insights from the Kroeber collection. In: Rakita GFM, Buikstra JE, Beck LA, Williams SR, editors. *Interacting with the dead: perspectives on mortuary archaeology for the new millennium*. Gainesville: University Press of Florida. p 251–276.
- Isbell WH. 1989. Honcopampa: was it a Huari administrative centre? In: Czwarno RM, Meddens FM, Morgan A, editors. *Nature of Wari: a reappraisal of the Middle Horizon Period in Peru*. BAR International Series, 525. Oxford: Archaeopress. p 98–114.
- Isbell WH, Cook AG. 2002. A new perspective on Conchopata and the Andean Middle Horizon. In: Silverman H, Isbell WH, editors. *Andean archaeology II: art, landscape, and society*. New York: Kluwer Academic Press. p 249–305.
- Isbell WH, McEwan GF. 1991. Huari administrative structure: prehistoric monumental architecture and state government. Washington, DC: Dumbarton Oaks Research Library and Collection.
- Kellner CM. 2002. Coping with environmental and social challenges in prehistoric Peru: bioarchaeological analyses of Nasca populations. Ph.D. dissertation, Santa Barbara: University of California.
- Kelly RC. 2000. Warless societies and the origin of war. Ann Arbor: University of Michigan Press.
- Ketteman WG. 2002. New dates from the Huari empire: chronometric dating of the prehistoric occupation of Conchopata, Ayacucho, Peru. Master thesis. New York: Binghamton University, State University of New York.
- Lambert PM. 2002. The archaeology of war: a North American perspective. *J Archaeol Res* 10:207–241.
- Lovell NC. 1997. Trauma analysis in paleopathology. *Yearbk Phys Anthropol* 40:139–170.
- Lumbreras LG. 1974. The peoples and cultures of ancient Peru. Washington: Smithsonian Institution Press.
- McEwan GF. 2005. *Pikillacta: the Wari empire in Cuzco*. Iowa City: University of Iowa Press.
- Meindl RS, Lovejoy CO. 1985. Ectocranial suture closure: a revised method for the determination of skeletal age at death based on the lateral-anterior sutures. *Am J Phys Anthropol* 68:57–66.
- Menzel D. 1964. Style and time in the Middle Horizon. *Nawpa Pacha* 2:1–105.
- Neira Avendano M, Coelho VP. 1972. Enterramientos de cabezas de la cultura Nasca. *Revista do Museu Paulista* 20:109–142.
- Ochatoma JP. 2007. *Alfareros del imperio Huari: vida cotidiana y áreas de actividad en Conchopata*. Ayacucho: Universidad Nacional de San Cristóbal de Huamanga Facultad de Ciencias Sociales.
- Ochatoma JP, Cabrera MR. 2002. Religious ideology and military organization in the iconography of a D-shaped ceremonial precinct at Conchopata. In: Silverman H, Isbell WH, editors. *Andean archaeology II: art, landscape, and society*. New York: Kluwer Academic Press. p 225–247.
- Ortner DJ, Kimmerle EH, Diez M. 1999. Probable evidence of scurvy in subadults from archaeological sites in Peru. *Am J Phys Anthropol* 108:321–331.
- Pipes R. 1991. *The Russian revolution*. New York: Vintage Books.

- Proulx DA. 1971. Headhunting in Ancient Peru. *Archaeology* 24:16–21.
- Proulx DA. 1989. Nasca trophy heads: victims of warfare or ritual sacrifice? *Cultures in conflict: current archaeological perspectives*. Calgary: Archaeological Association, University of Calgary, p. 73–85.
- Proulx DA. 2001. Ritual uses of trophy heads in ancient Nasca society. In: Benson EP, Cook AG, editors. *Ritual sacrifice in ancient Peru*. Austin: University of Texas Press. p 119–136.
- Schoeninger MJ. 1989. Reconstructing prehistoric human diet. In: Price TD, editor. *The chemistry of prehistoric human bone*. Cambridge: Cambridge University Press. p 38–67.
- Schreiber KJ. 1992. Wari imperialism in Middle Horizon Peru. Ann Arbor: Museum of Anthropology, University of Michigan.
- Schreiber KJ. 2001. The Wari empire of Middle Horizon Peru: the epistemological challenge of documenting an empire without documentary evidence. In: Alcock SE, D'Altroy TN, Morrison KD, Sinopoli CM, editors. *Empires*. Cambridge: Cambridge University Press. p 70–92.
- Scott EC. 1979. Dental wear scoring technique. *Am J Phys Anthropol* 51:213–218.
- Silverman H. 1993. Cahuachi in the ancient Nasca world. Iowa City: University of Iowa Press.
- Smith BH. 1984. Patterns of molar wear in hunter-gatherers and agriculturalists. *Am J Phys Anthropol* 63:39–56.
- Stuart-Macadam P. 1985. Porotic hyperostosis: representative of a childhood condition. *Am J Phys Anthropol* 66:391–398.
- Stuart-Macadam P. 1987. Porotic hyperostosis: new evidence to support the anemia theory. *Am J Phys Anthropol* 74:521–526.
- Tesar L, Rao Y. 2007. Wari warfare and trophy taking: more than just a skull. Presented at 72nd Annual Meeting of the Society for American Archaeology, Austin, TX.
- Tung TA. 2003. A bioarchaeological perspective on Wari imperialism in the Andes of Peru: a view from heartland and hinterland skeletal populations. Ph.D. dissertation. Chapel Hill: University of North Carolina.
- Tung TA. 2007a. From corporeality to sanctity: transforming bodies into trophy heads in the prehispanic Andes. In: Chacon RJ, Dye DH, editors. *The taking and displaying of human trophies by Amerindians*. New York: Springer Press. p 477–500.
- Tung TA. 2007b. Trauma and violence in the Wari empire of the Peruvian Andes: warfare, raids, and ritual fights. *Am J Phys Anthropol* 133:941–956.
- Tung TA, Del Castillo M. 2005. Una visión de la salud comunitaria en el valle de Majes durante la época Wari: Muerte y evidencias funerarias en los Andes Centrales: Avances y perspectivas. Lima: Universidad Nacional de Federico Villarreal. p 149–172.
- Tung TA, Cook AG. 2006. Intermediate elite agency in the Wari empire: the bioarchaeological and mortuary evidence. In: Elson C, Covey RA, editors. *Intermediate elites in Pre-Columbian states and empires*. Tucson: University of Arizona Press. p 68–93.
- Tung TA, Knudson KJ. 2006. Identifying the origin of Wari trophy heads in the ancient Andes using bioarchaeology and archaeological chemistry. Paper presented at the 75th Annual Meeting of the American Association of Physical Anthropologists.
- Ubelaker DH. 1989. *Human skeletal remains: excavation, analysis, interpretation*. Washington, DC: Taraxacum Press.
- Verano JW. 1995. Where do they rest? The treatment of human offerings and trophies in ancient Peru. In: Dillehay TD, editors. *Tombs for the living: Andean mortuary practices*. Washington, DC: Dumbarton Oaks. p 189–189.
- Verano JW. 2001. The physical evidence of human sacrifice in ancient Peru. In: Benson EP, Cook AG, editors. *Ritual sacrifice in Ancient Peru*. Austin: University of Texas Press. p 165–165.
- Waldron T. 1996. Legalized trauma. *Int J Osteoarch* 6:114–118.
- Walker PL. 1985. Anemia among prehistoric Indians of the American Southwest. In: Merbs FC, Miller RJ, editors. *Health and disease in the Prehistoric Southwest*. Tempe: Arizona State University. p 139–139. *Anthropological Research Papers*.
- Walker PL. 1997. Wife beating, boxing, and broken noses: skeletal evidence for the cultural patterning of violence. In: Martin DK, Frayer DW, editors. *Troubled times: violence and warfare in the past*. Australia: Gordon and Breach Publishers. p 145–145.
- Walker PL. 2001. A bioarchaeological perspective on the history of violence. *Ann Rev of Anthropol* 30:573–596.
- Walker PL, Long J. 1977. An experimental study of the morphological characteristics of toolmarks. *Am Antiq* 42:605–616.
- Walker PL, Miller KWP, Richman R. 2008. Time, temperature, and oxygen availability: an experimental study of the effects of environmental conditions on the color and organic content of cremated bone. In: Schmidt CW, Symes SA, editors. *The analysis of burned human remains*. Amsterdam: Academic Press. p. 129–136.
- Wapler U, Crubézy E, Schultz M. 2004. Is cribra orbitalia synonymous with anemia? Analysis and interpretation of cranial pathology in Sudan. *Am J Phys Anthropol* 123:333–339.
- White TD. 1992. *Prehistoric cannibalism at Mancos 5MTUMR-2346*. Princeton: Princeton University Press.
- Williams PR. 2001. Cerro Baúl: a Wari center on the Tiwanaku frontier. *Lat Am Antiq* 12:67–83.
- Williams SR, Forgey K, Klarich E. 2001. An osteological study of Nasca trophy heads collected by A.L. Kroeber during the Marshall field expeditions to Peru. Chicago: Field Museum of Natural History.